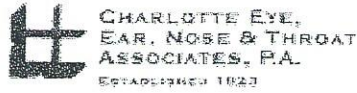


Mom's
copy



Blakeney Office
5933 Blakeney Park Dr
Charlotte, NC 28277
704-295-3311 704-295-3324

THIS DOCUMENT WAS CREATED ON: 01/26/2011 16:26:24 BY: Erin B. Goshorn, M.D.

Exam Date: Wednesday, January 26, 2011

PATIENT NAME: MATTHEW WULF

PATIENT ID: 317996 DOB: 12/3/1997 AGE: 13
GENDER: Male Race: Caucasian ACCOMPANIED BY: mother

PRIMARY CARE PHYSICIAN: KRISTIN K STRANGE MD

History

Chief Complaint/Reason For Visit: F/U bil optic atrophy, rod-cone dystrophy, XT. No drifting noticed. Wears gls FT. Reading and scanning really well. Using zoom-twix to read with.

HISTORY OF PRESENT ILLNESS:

PROBLEM: optic atrophy and cone-rod dystrophy
LOCATION: retina and brain
SEVERITY: severe
DURATION: 6 months follow up
ASSOCIATED SS: XT
HPI was reviewed by doctor EBG

996 02/17/11 14:04 Page 3

ANTERIOR VITREOUS:	cortex &, nucleus nl clear	nucleus nl clear
PRESSURES:	FTS	FTS
DATE-TIME:	1/26/2011 4:16:36 PM	1/26/2011 4:16:36 PM
TECHNICIAN:	EBG	EBG

FUNDUS EXAM:

CUP TO DISC:	0.2	0.2
OPTIC DISC:	+3 generalized waxy pallor	+3 generalized waxy pallor
VITREOUS:	clear	clear
MACULA:	decreased foveal reflex	decreased foveal reflex
VESSELS:	+ 3 attenuation	+ 3 attenuation
PERIPHERY:	no pigment stippling	no pigment stippling

45 minutes spent on exam and discussion today

Impression

PROBLEM: